Screening Basics:

1. Cancers that we miss and
   The Peripheral Glandular Zone

2. Screen detected cancers in the “under 50’s”
   - How Subtle are they ?

3. The Radiopacity of Circumscribed Cancers –
   - Implications for Recall

MonashHealth

BreastScreen saves lives

Cancers that we miss:
the importance of the
Peripheral Glandular Zone

Ashwini Devapalasundaram FRANZCR
&
John Waugh FRANZCR

MonashHealth

The Peripheral glandular zone (PGZ) – 1cm wide band

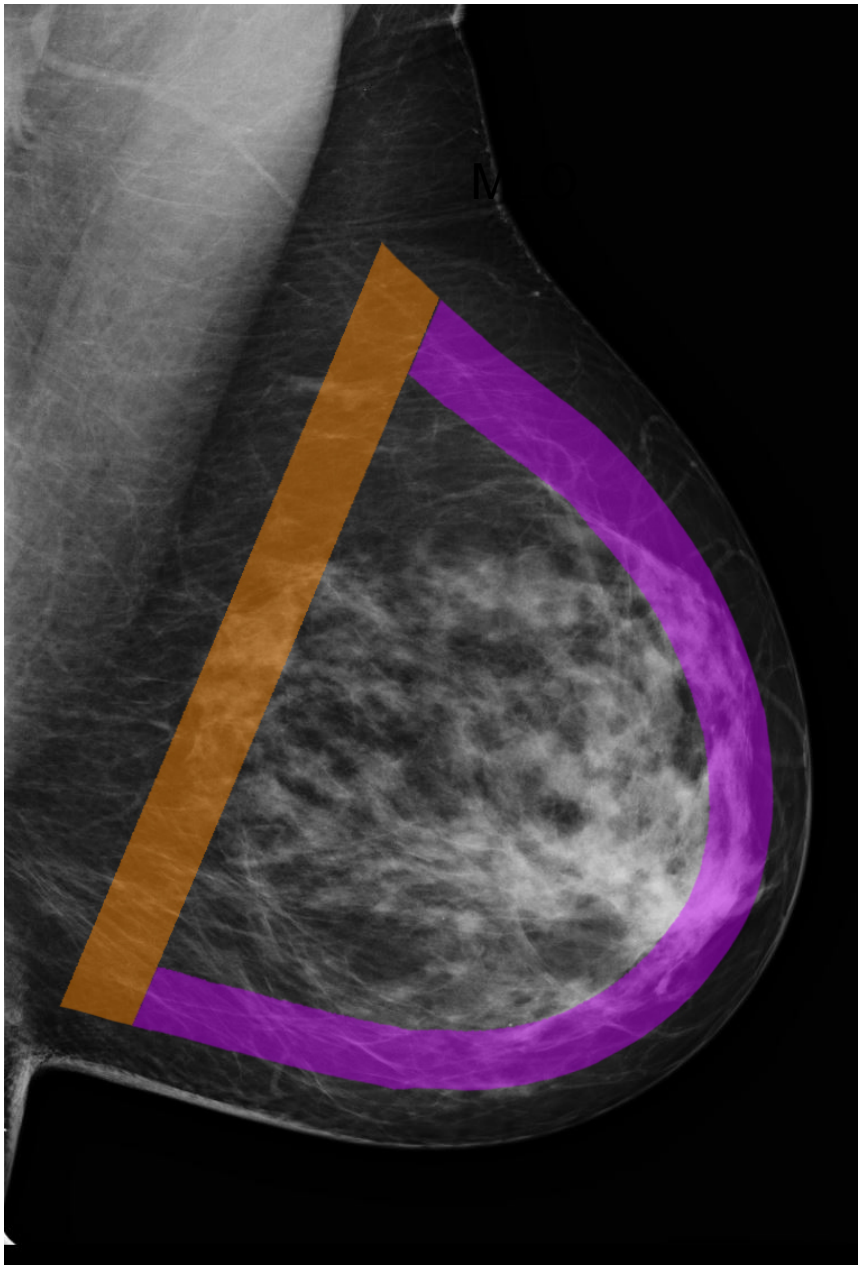

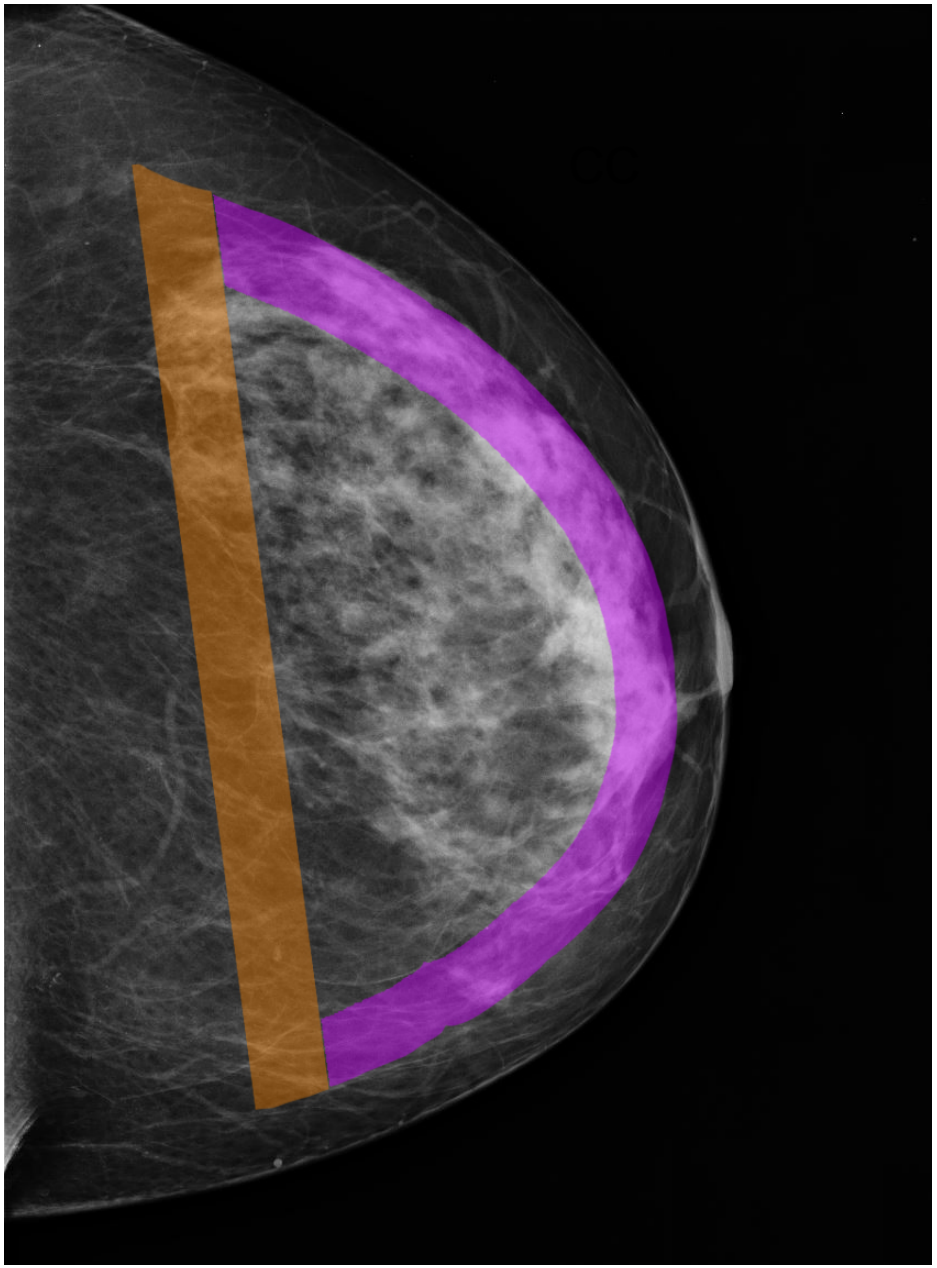

Background article 1:

- 1997 article :

Stacy K. Goergen, FRACR • Jill Evans, FRACR • Gary P. B. Cohen, FRACR
Jamie H. MacMillan, MSc

Characteristics of Breast Carcinomas Missed by Screening Radiologists[1]

1997 Radiology Article

MonashHealth

BreastScreen saves lives

Background article 2:

- 1993 article :

Breast Imaging

Adam Stacey-Clear, MS, FRCS • Kathleen A. McCarthy, MD • Deborah A. Hall, MD
Elizabeth Pile-Spellman, MD • George White, MD • Carol A. Hulka, MD
Gary J. Whitman, MD • Elkan F. Halpern, PhD • Daniel B. Kopans, MD

Mammographically Detected Breast Cancer: Location in Women under 50 Years Old[1]

1993 Radiology Article: from Harvard / Massachusetts General H Group

MonashHealth

BreastScreen saves lives

Background to 1997 Study

- Purpose to determine whether cancers missed at screening mammography have distinguishing characteristics
- If these characteristics could be identified it would possible to alert screening radiologists to factors that increase the likelihood of missing cancers

MonashHealth

BreastScreen saves lives

Background to 1993 Study

- Location of breast cancers has long been of interest to researchers
- Anecdotal observation that in women with dense breasts, cancers were more often found at the periphery of the parenchymal cone of fibroglandular tissue

MonashHealth

BreastScreen saves lives

Why are cancers frequently in the PGZ?

- In an average size breast the majority of the breast parenchyma lies in the peripheral zone.

Defining the Peripheral Glandular Zone (PGZ)

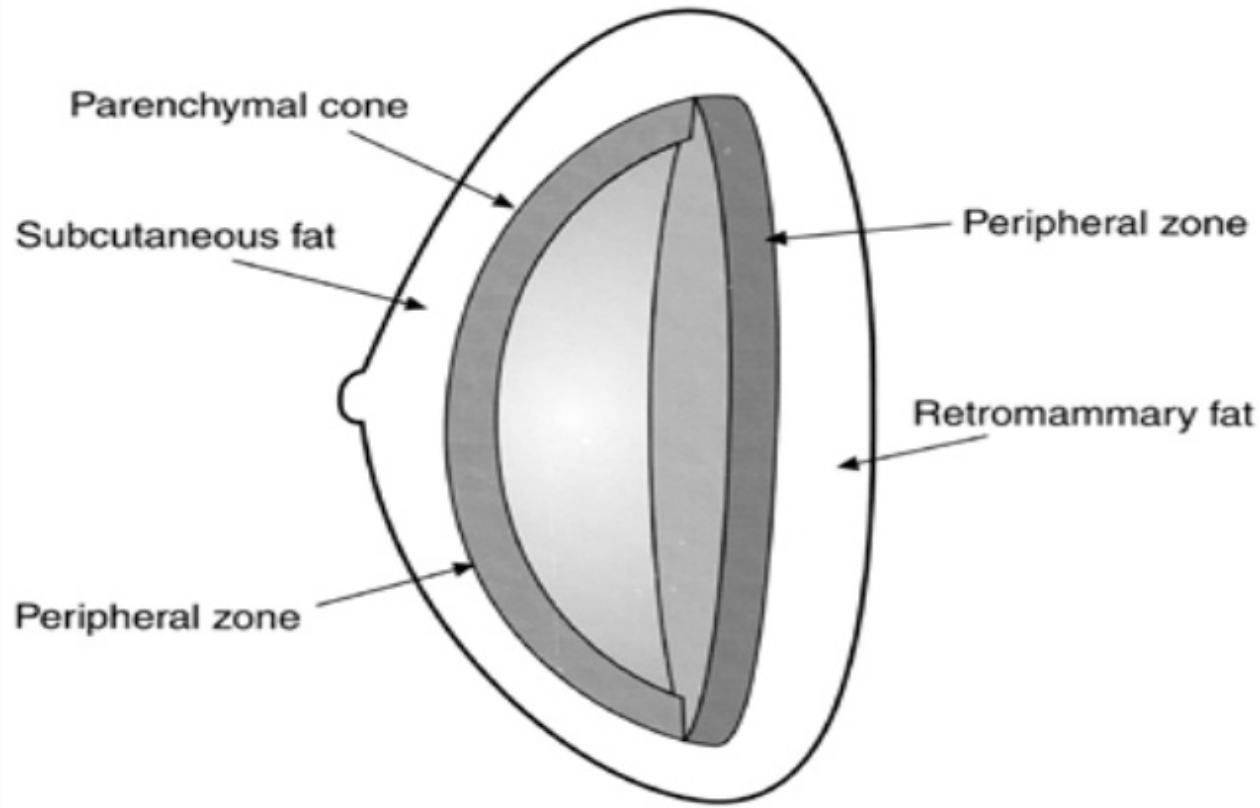

Breast cancer is often found at the periphery of the gland. This schematic depicts a zone 1 cm wide beneath the subcutaneous fat and anterior to the retromammary fat. More than 70% of breast cancers develop in this zone. For most women, depending on the size of the breast, more than 50% of the parenchyma is in this zone.

What volume of tissue lies in the PGZ?

- Assume breast is hemisphere

- Volume of tissue in PGZ can be calculated by subtracting the volume beneath this zone from the total volume of the breast parenchyma

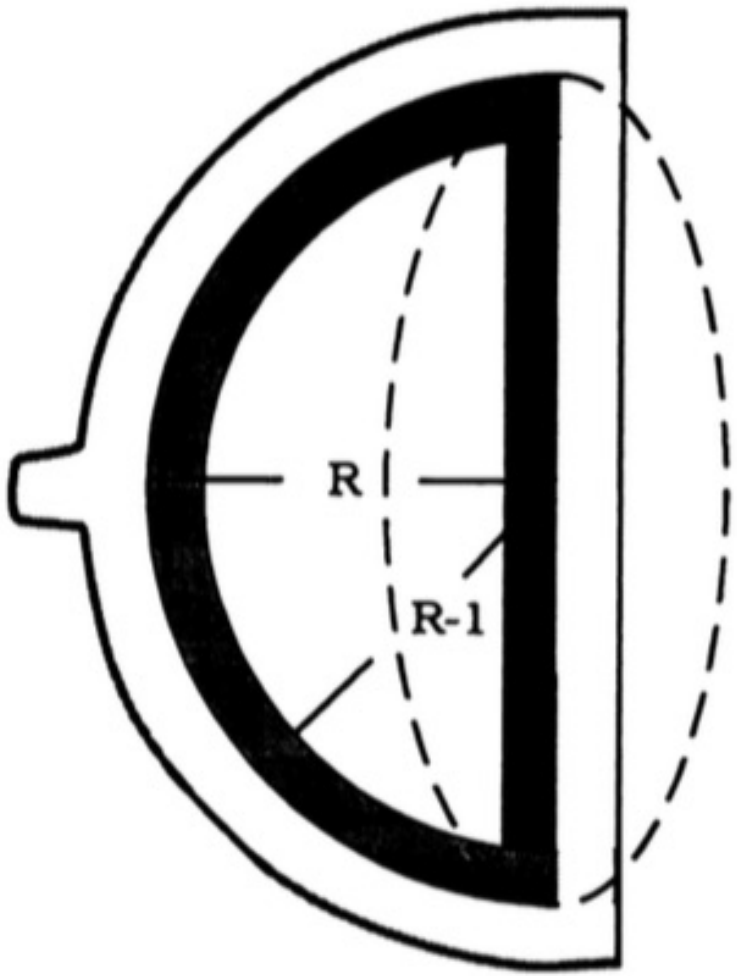

- For radii of 7cm or smaller more than 50% of the breast glandular tissue is within the peripheral zone

Radius of breast parenchyma	Volume within 1cm Zone (%)
4cm	78
5cm	68
6cm	60
7cm	52

Our study hypothesis

- At the tissue interphase in PGZ the variability in mammo' features -> Interpretation challenges

- Large proportion of Invasive cancers

  - missed by one reader

  - located in the PGZ

Method (Monash BreastScreen)

- 1 reader cancers were reviewed from 1st quarter 2013 to 1st quarter 2015 (incl)

- Total 140 consecutive invasive cancers

- Cancers analysed:
  - Location: peripheral zone or “other”
  - Recall category
  - Tumor size at surgery
  - Histology

MonashHealth

MLO

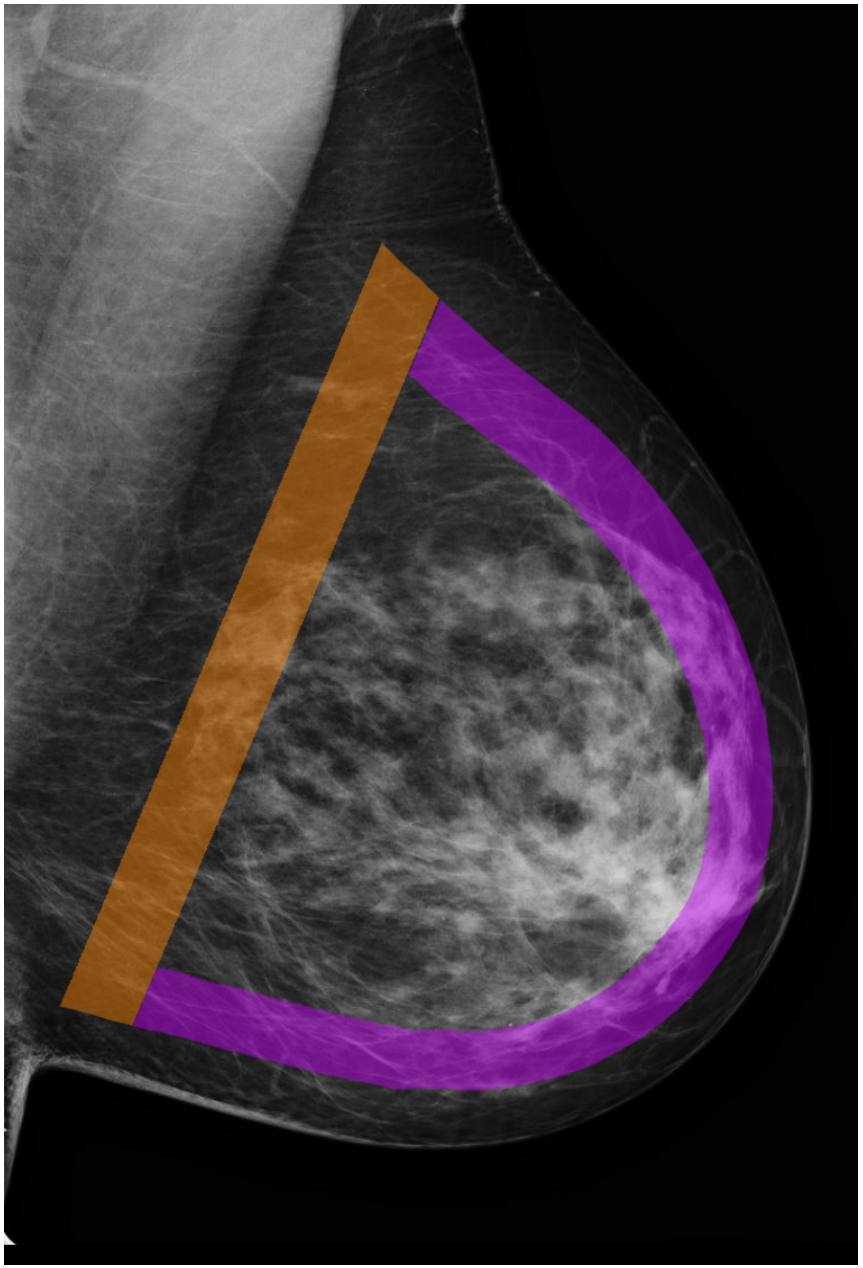

CC

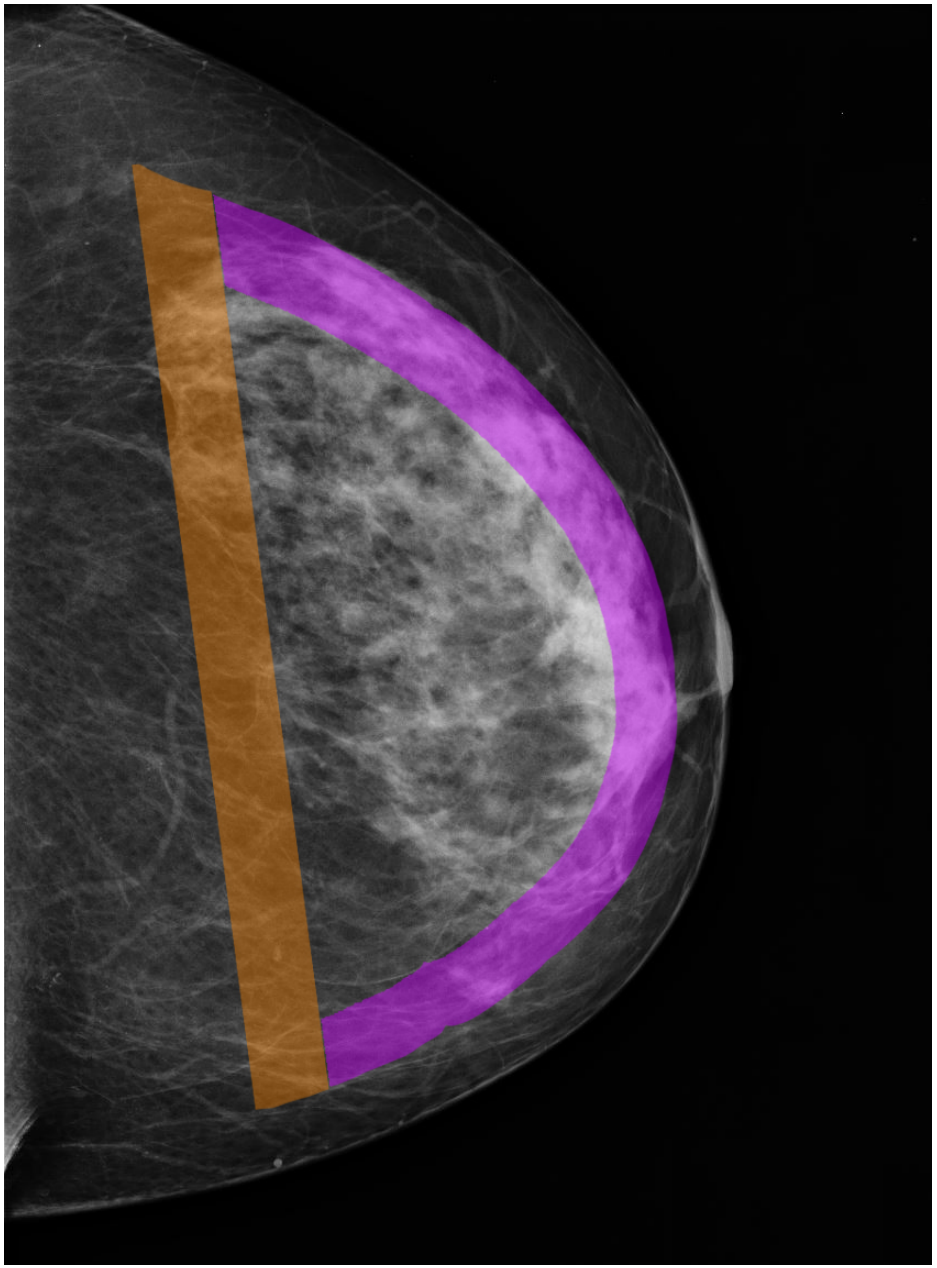

Our definition of PGZ

- 1cm of parenchyma deep to the subcutaneous tissue and anterior to the retromammary fat.

- A cancer was considered peripheral if on any projection, the centre of a mass was within 1cm of this parenchymal edge

Results: location

- 104 of 140 invasive cancers were in the peripheral zone
- 64 located posteriorly (including axillary tail)
- 40 located anteriorly

Results: location

- 74.3% of 1 reader cancers located in PGZ (104 of 140 CAs)
  - 61.5% posteriorly
  - 38.5% anteriorly

MonashHealth

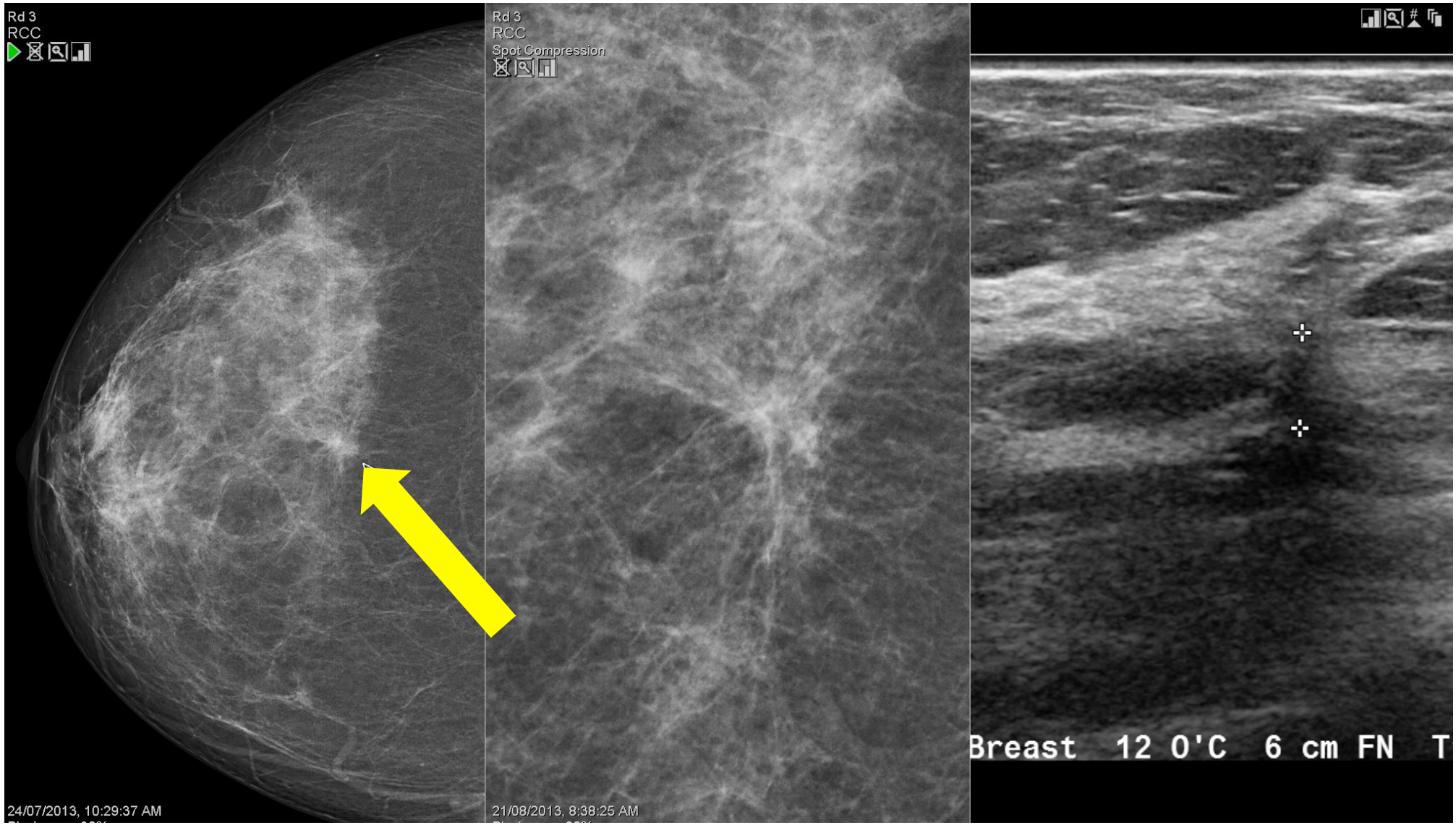
Rd 3
RCC
24/07/2013, 10:29:37 AM
Rd 3
RCC
Spot Compression
21/08/2013, 8:38:25 AM
Breast 12 O'C 6 cm FN T

Results: recall category

Digital recall category	Percentage of total
Mass	29.8%
Asymmetric density	21.2%
Architectural distortion	42.3%
Calcification	6.7%

Results: size

Mean size 18 mm
Median size 14mm

MonashHealth

Results: histology of PGZ cancers

Type	Number	% of all PGZ	% Posterior	% Anterior
IDC	88	84.6	62.5	37.5
ILC	13	12.5	69.2	30.8
All others*	3	2.9	0	100
TOTAL	104	100		

* Others included: mucinous & tubular

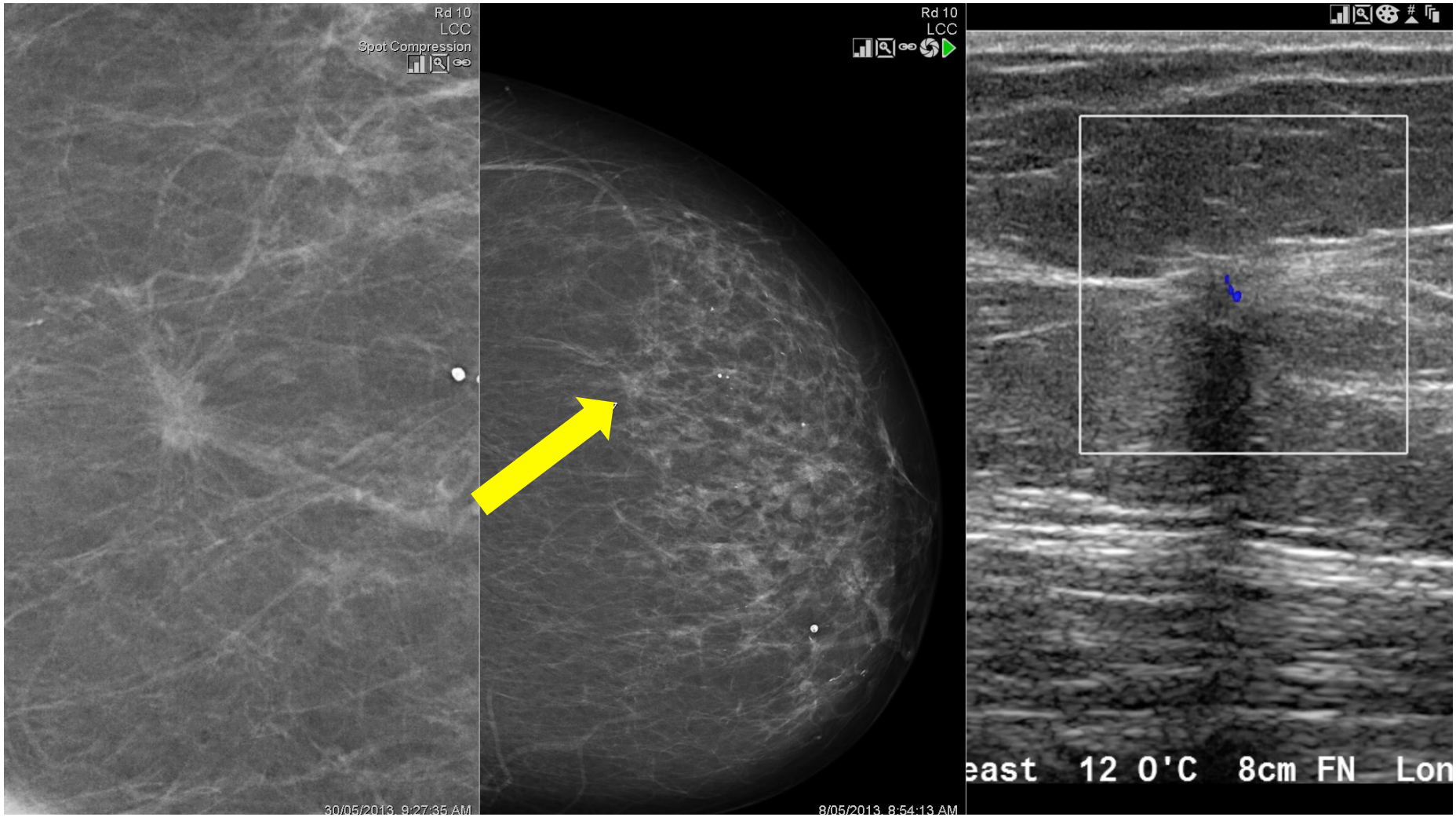
Rd 10
LCC
Spot Compression
30/05/2013, 9:27:35 AM
Rd 10
LCC
8/05/2013, 8:54:13 AM
east 12 O'C 8cm FN Lon

Zoomed Right and Left CC images

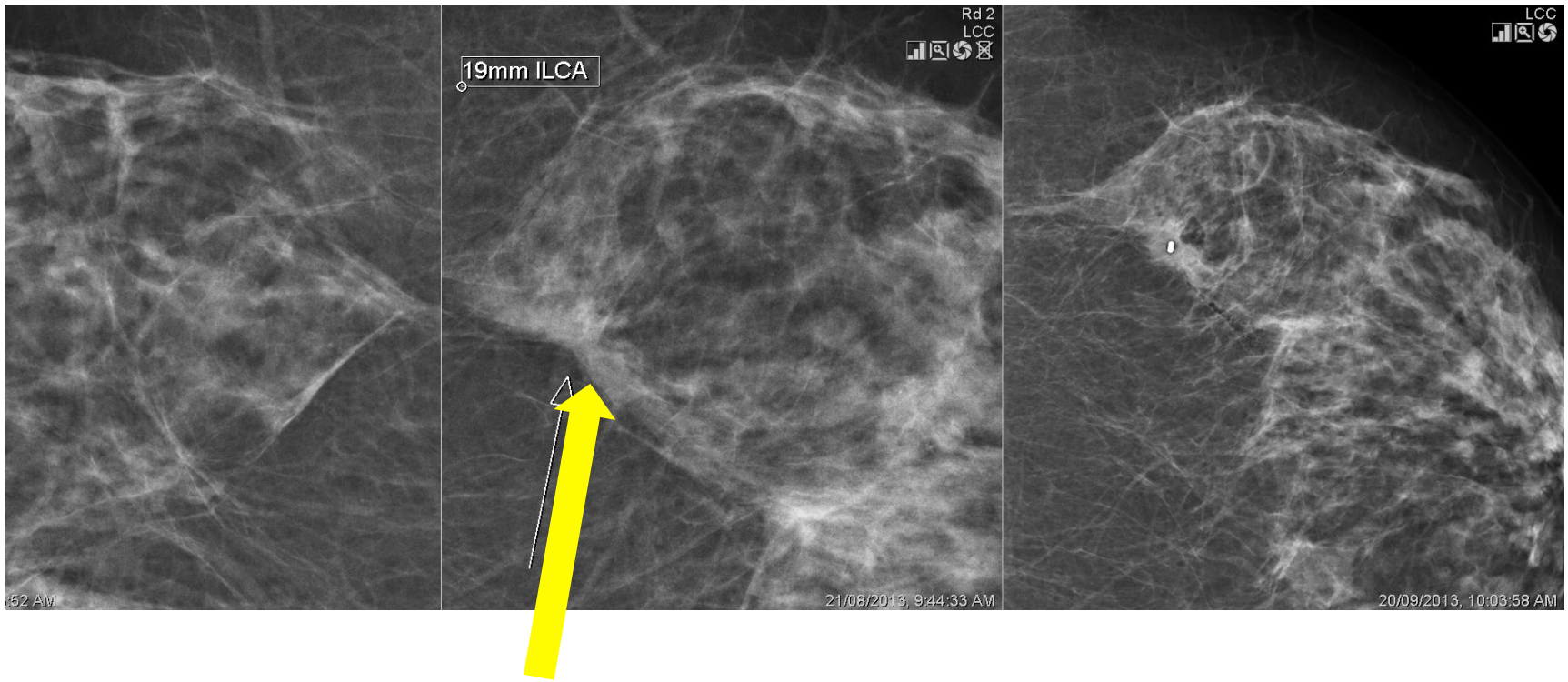

New finding in the Left Posterior Peripheral Glandular Zone (PGZ)

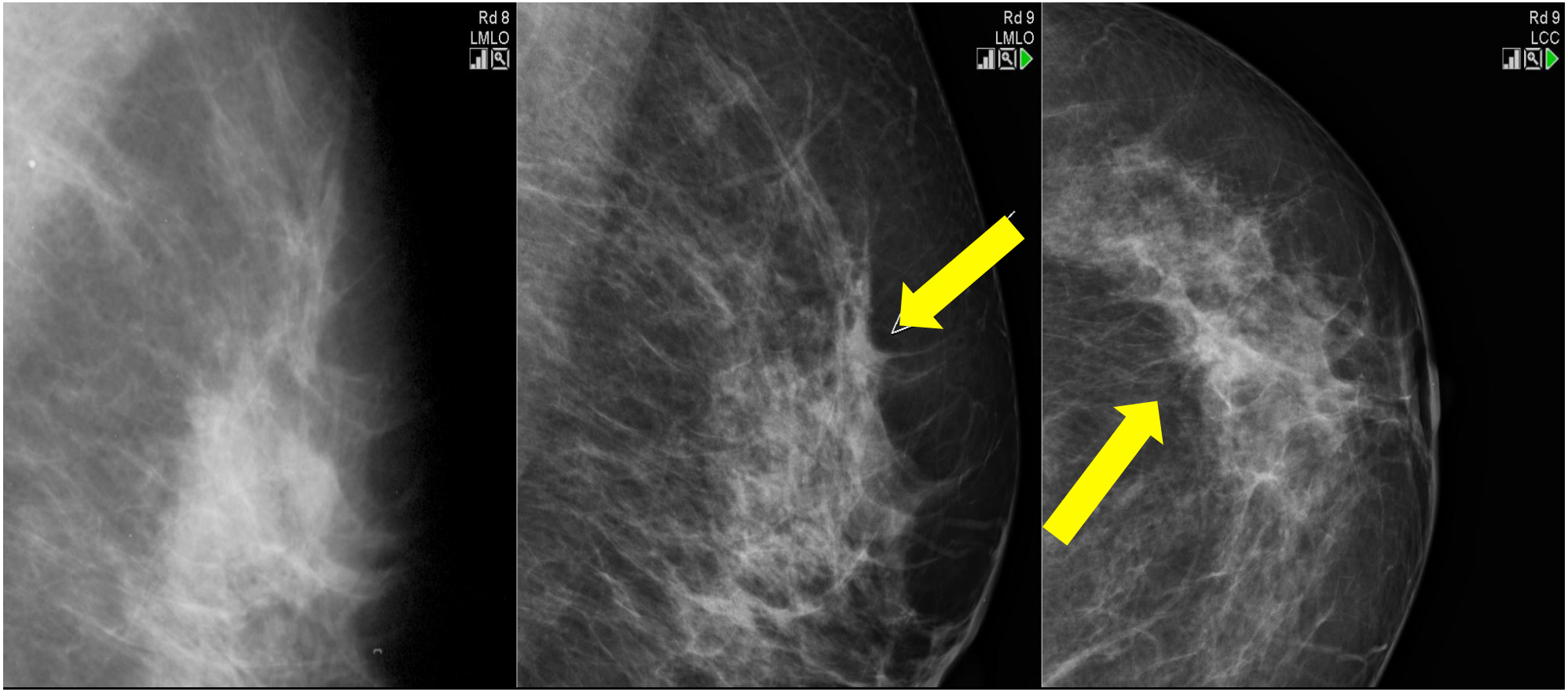

Missed CA in Anterior PGZ - Left MLO

presented as Interval 20mm Grade 3 IDCA
14 months later – with nodal involvement

6mm IDCA developed
In anterior PGZ

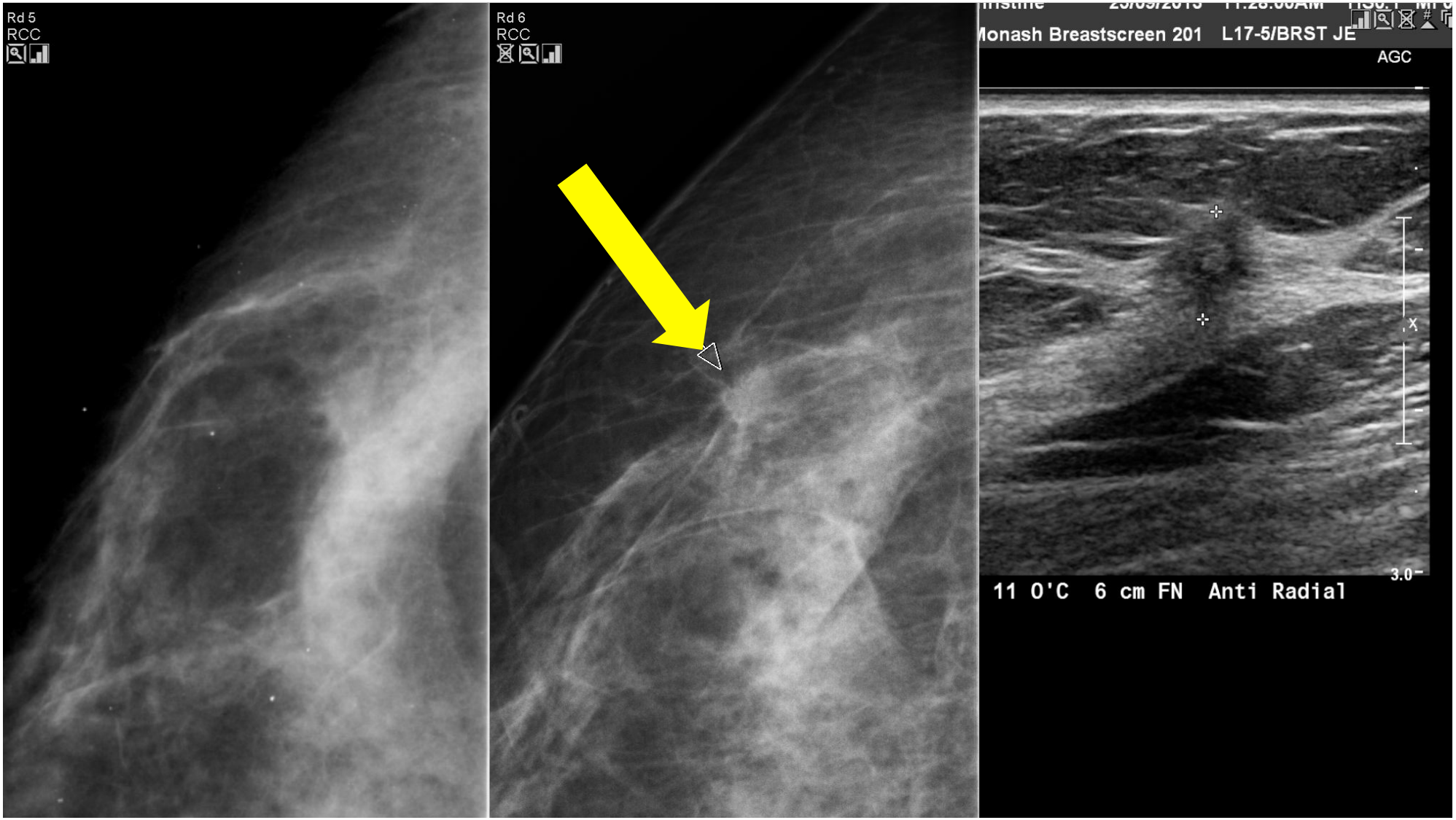

Conclusion: 1

- Readers clearly have difficulty interpreting the interphase of the Fibro-glandular tissue and adjacent more radiolucent fat

- Some readers routinely review and detect small tumours in the PGZ

- Commenced feedback to our readers after study period (mid 2015)

Readers recommended to review the peripheral glandular zone

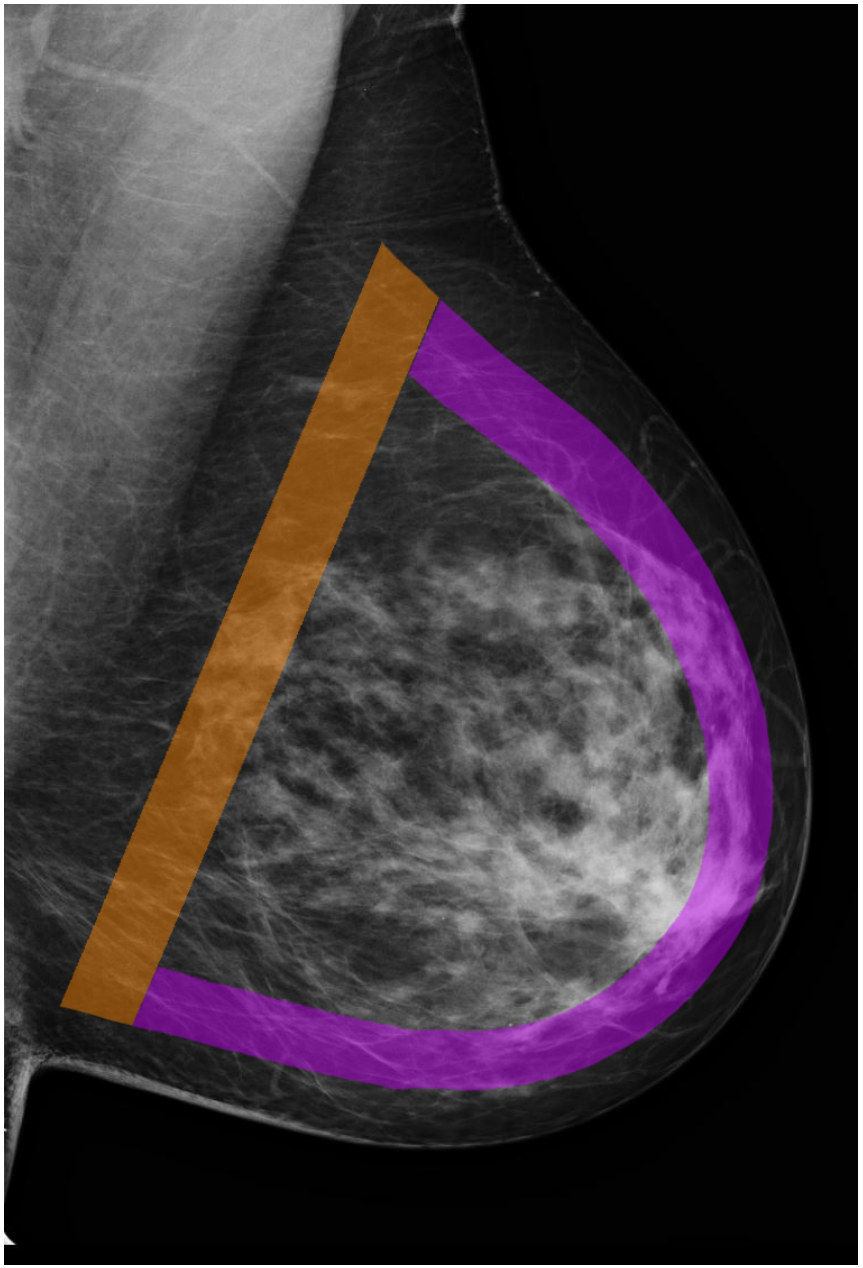

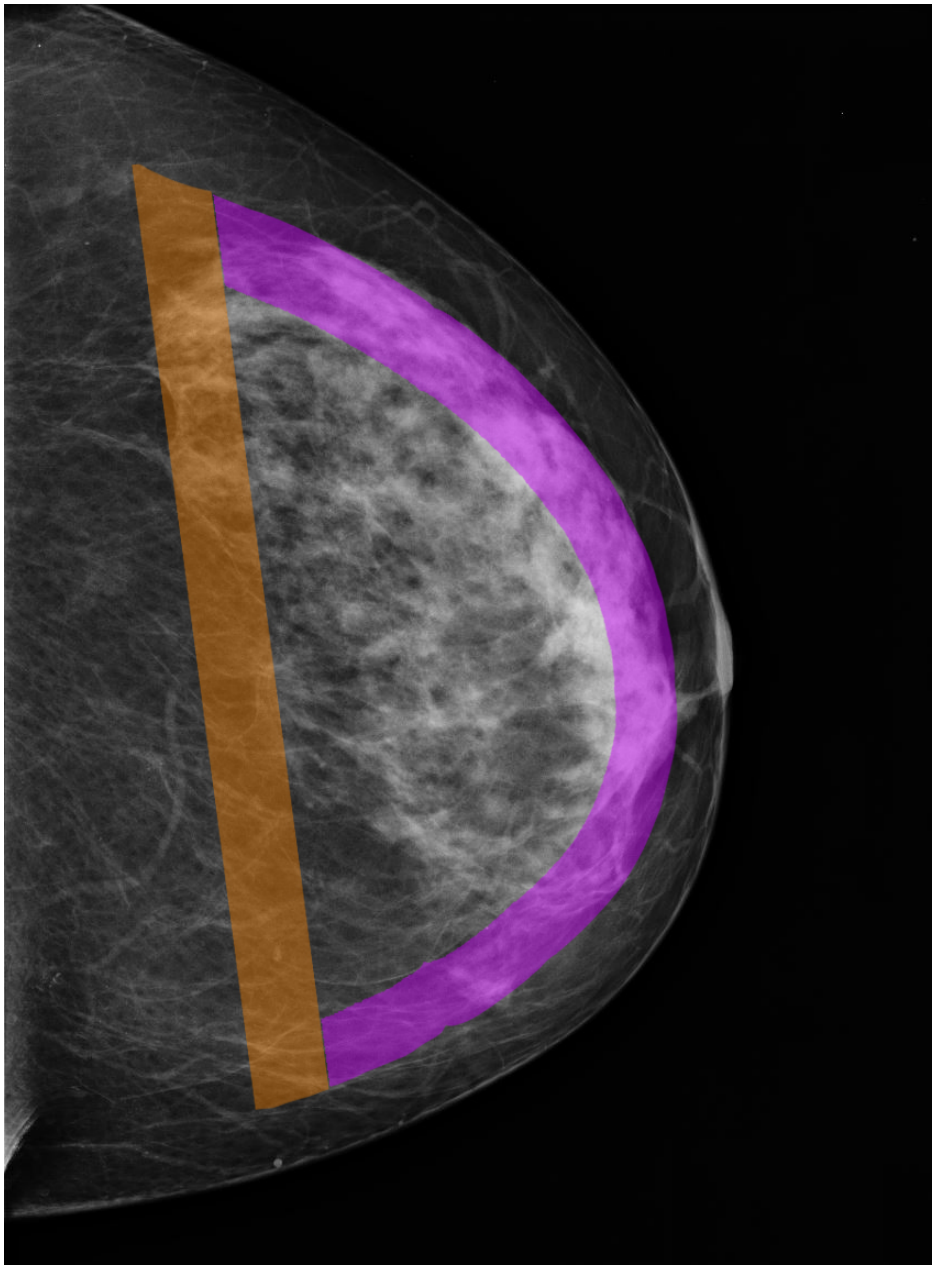

Early Outcome Data: Round 1 Cancer Detection

Service Invasive Cancer Detection Rates (50-69 years)

	Jan-Jun '14	Jul-Dec '14	Jan-Jun '15	Jul-Dec '15	Jan-Jun '16
Round 1	79.3	69.0	62.0	89.4	89.1
NAS	50.0	50.0	50.0	50.0	50.0

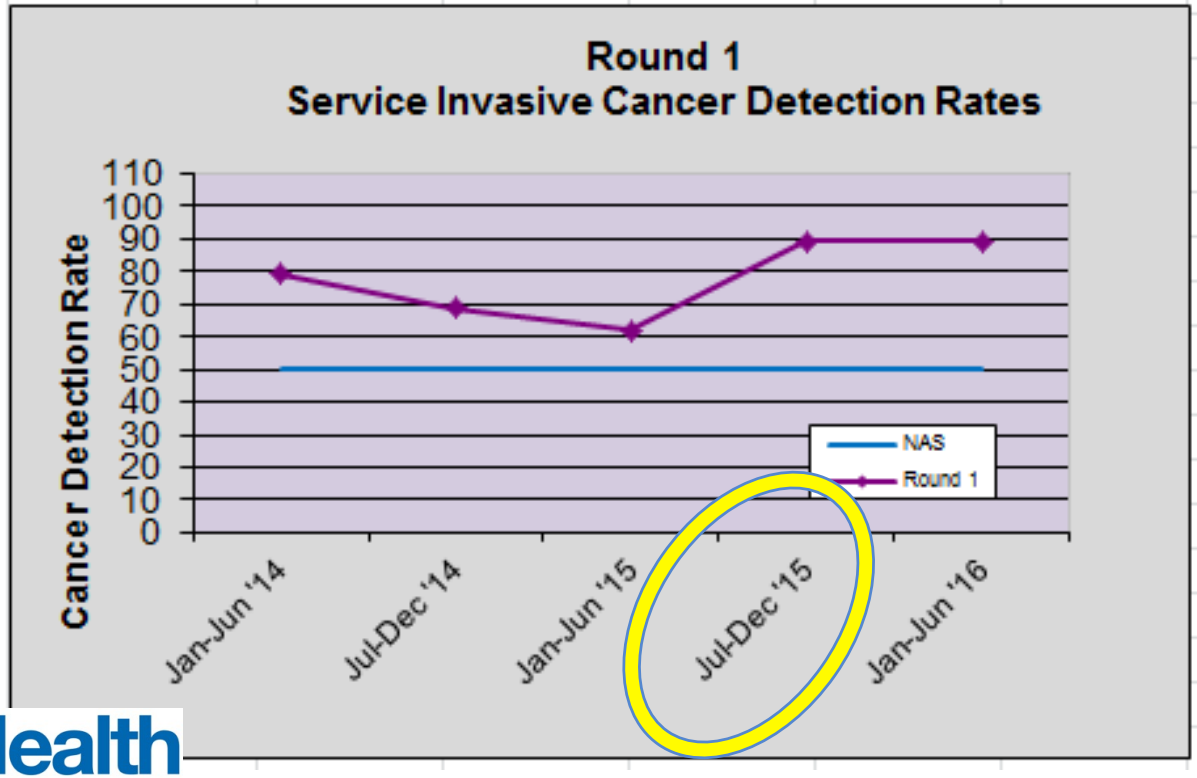

Increase did not reach level of Statistical Significance $P > 0.05$

MonashHealth

BreastScreen saves lives

Conclusions : 2

- The PGZ was the location of 74.3% of invasive CAs missed by one Reader - 32 month study period
- Impact on the Efficacy of screening with large percentage CAs <20 mm diameter
- The Periphery of the fibro-glandular tissue is therefore an important “Area of Review” for readers
- “Architectural distortion” was the subtle finding, most often missed in the Peripheral Glandular Zone

2 cases of spic/arc since study reported back to our readers

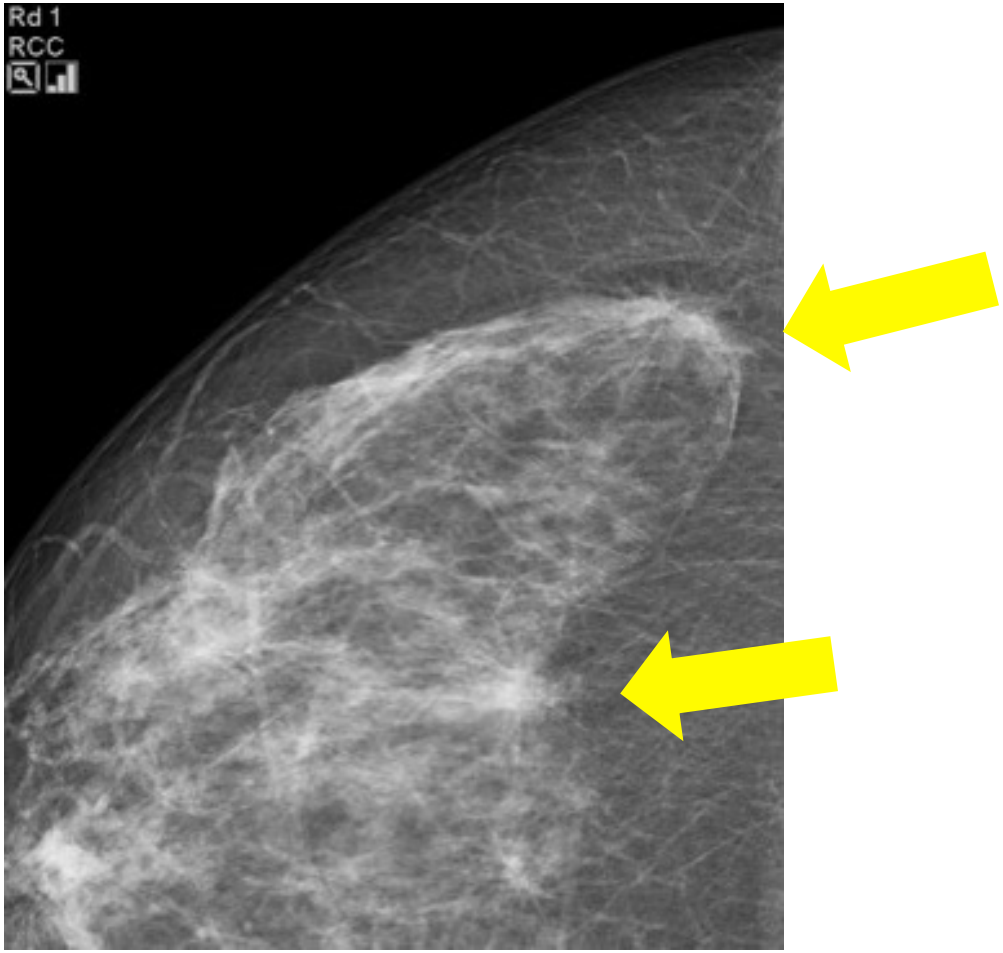

I5 mm and 6mm IDCA's at M1 and M3 respectively

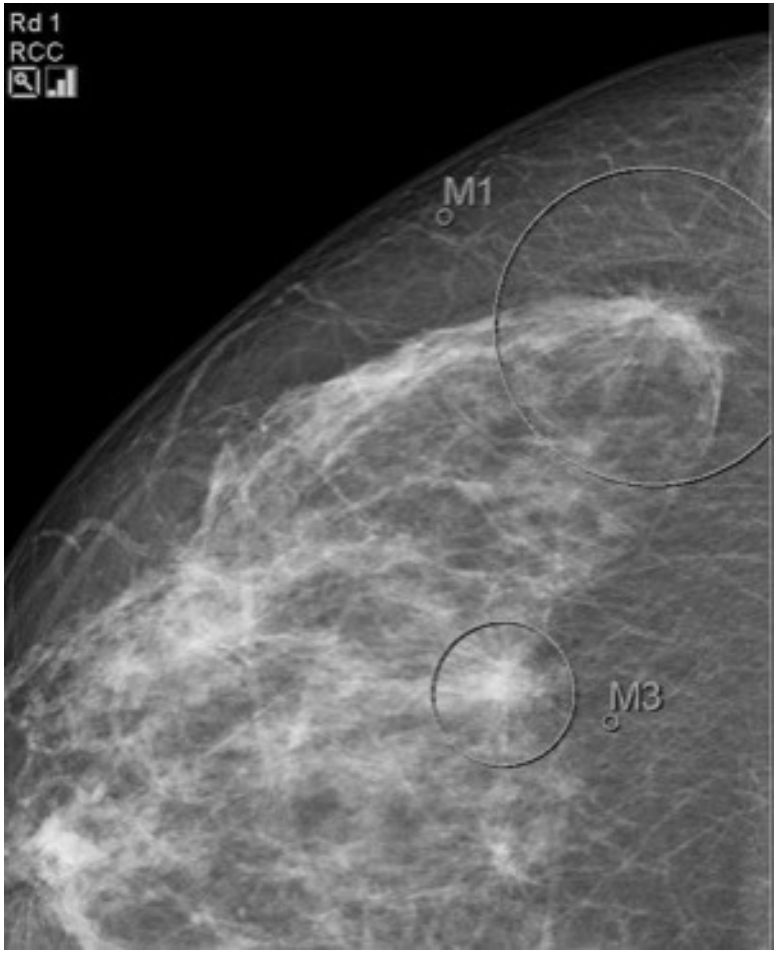

5mm Grade 2 IDCA detected